

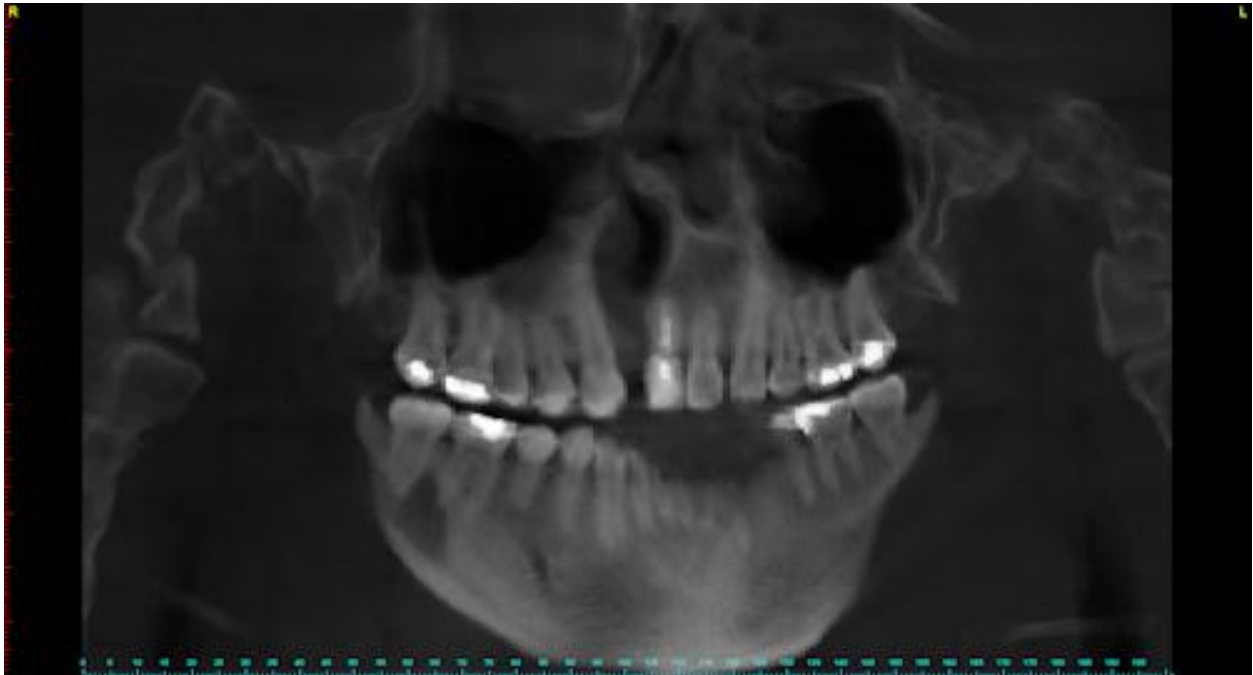
Cleft Lip and Palate

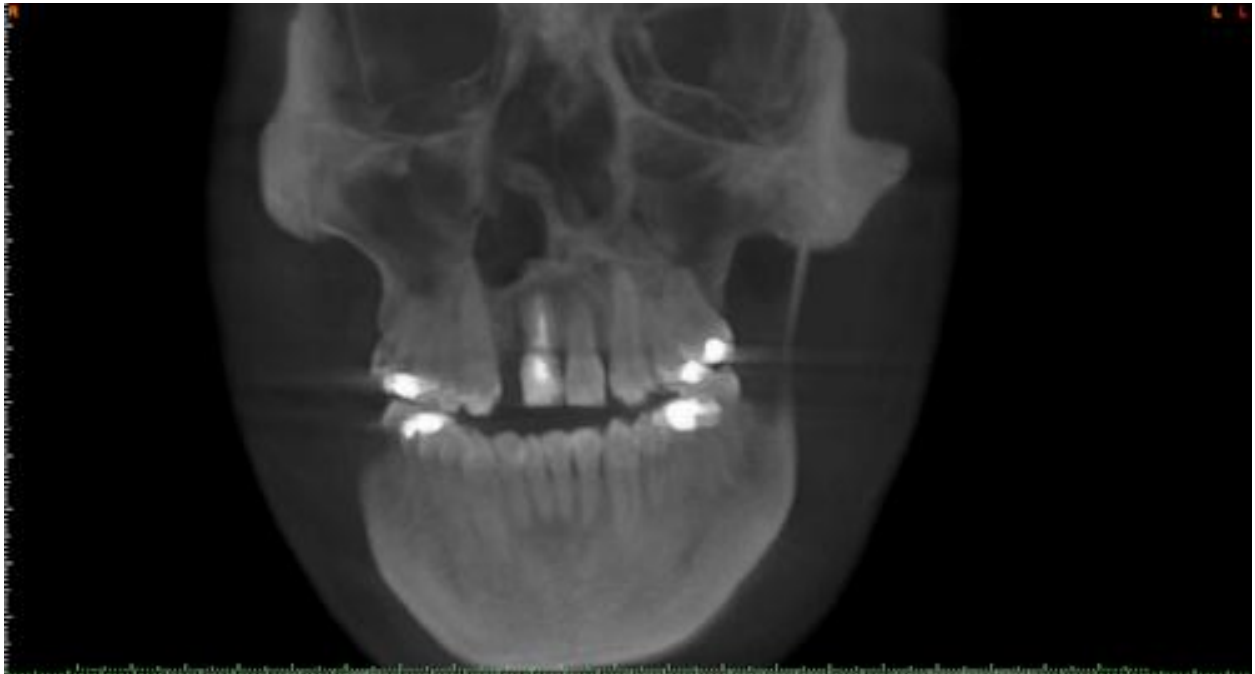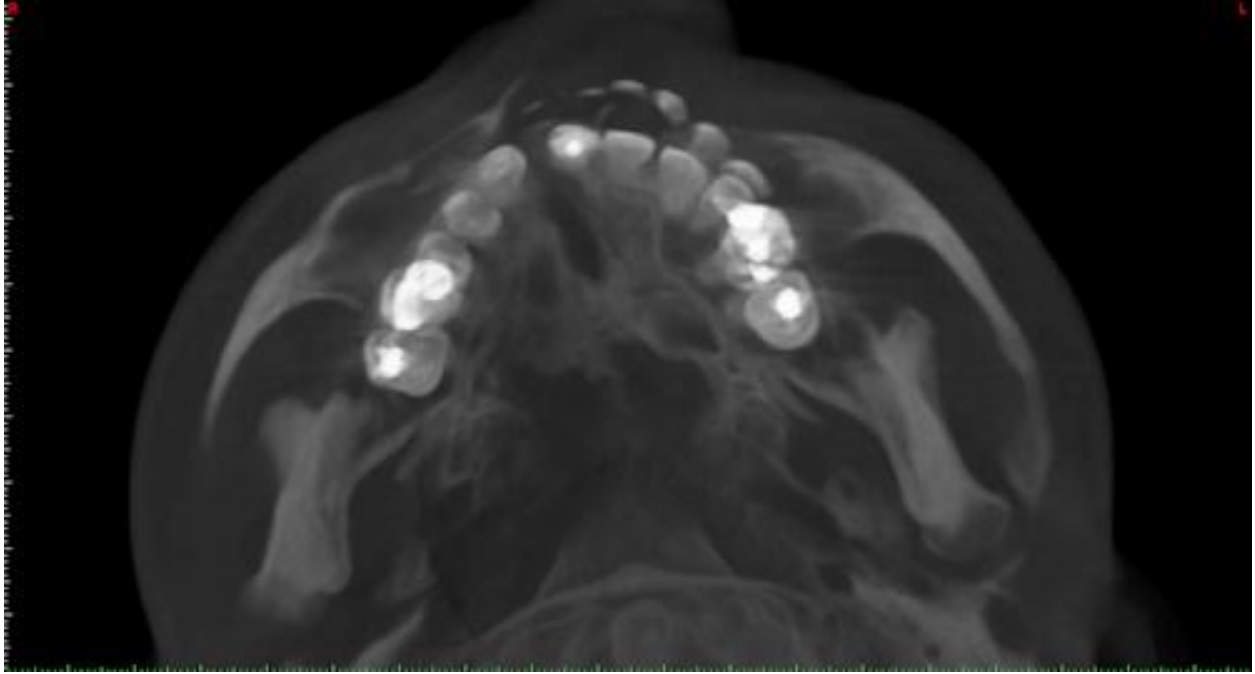
Three-dimensional imaging techniques are increasing in importance compared with conventional radiological imaging techniques in patients with cleft lip and palate. For these patients, it is important to obtain detailed imaging of the osseous cleft region, the teeth and the tooth germs especially in orthodontic planning and surgical operations such as osteoplasty. Considerations in regard to the number of teeth present, their three-dimensional orientation, prognosis of the teeth, bone quality and the amount of bone available arise constantly in everyday routine.

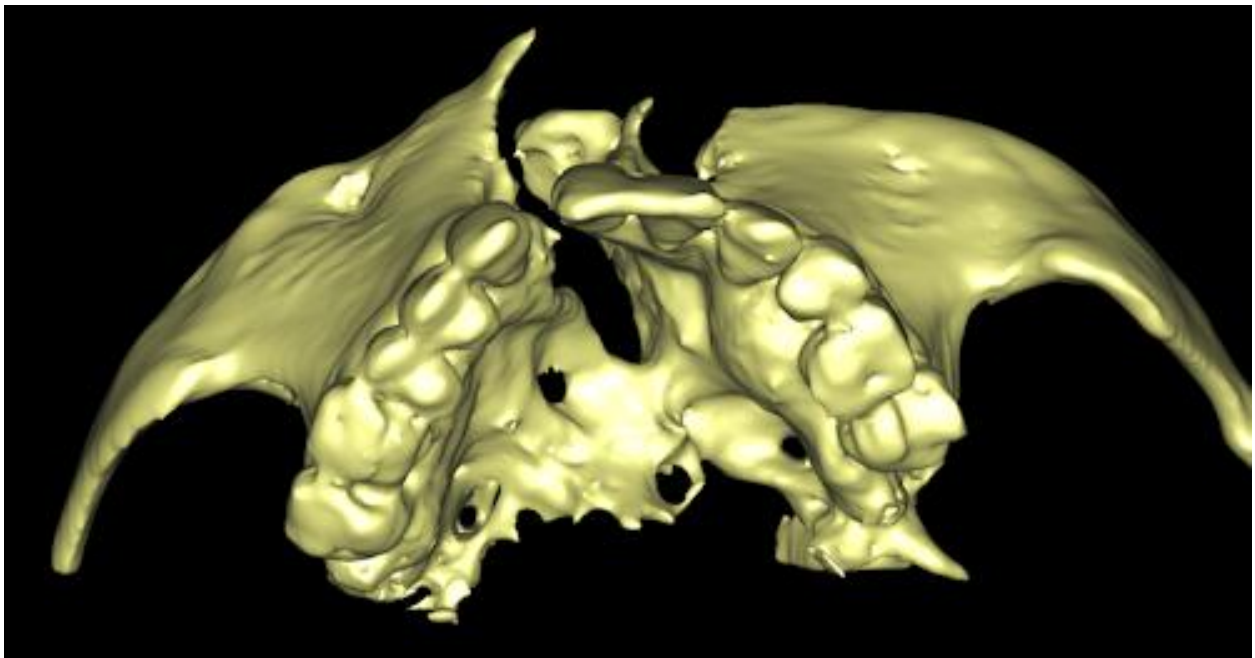
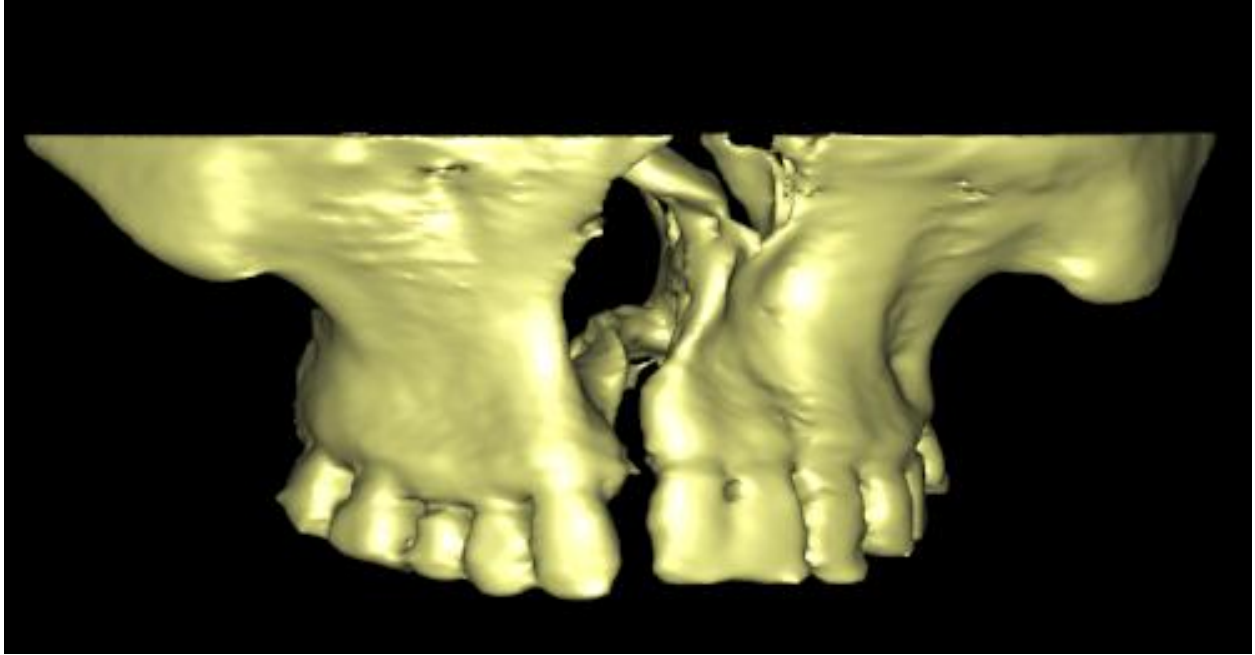
This case was referred to CBCT for surgical planning and assessment.

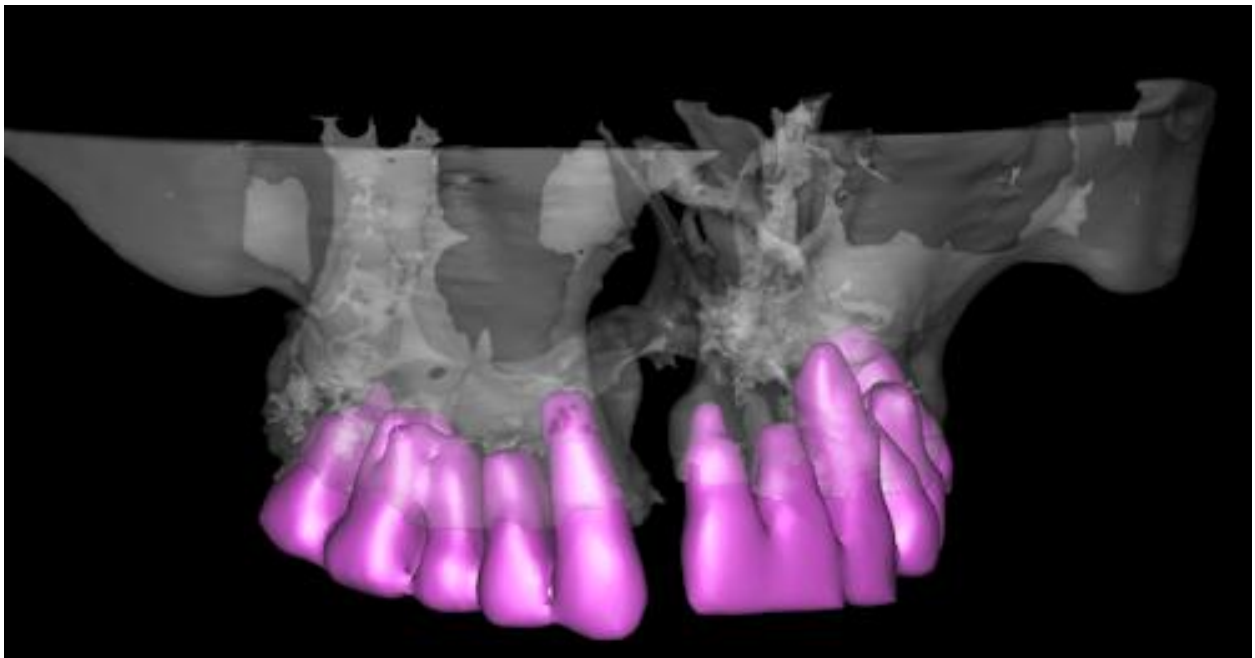
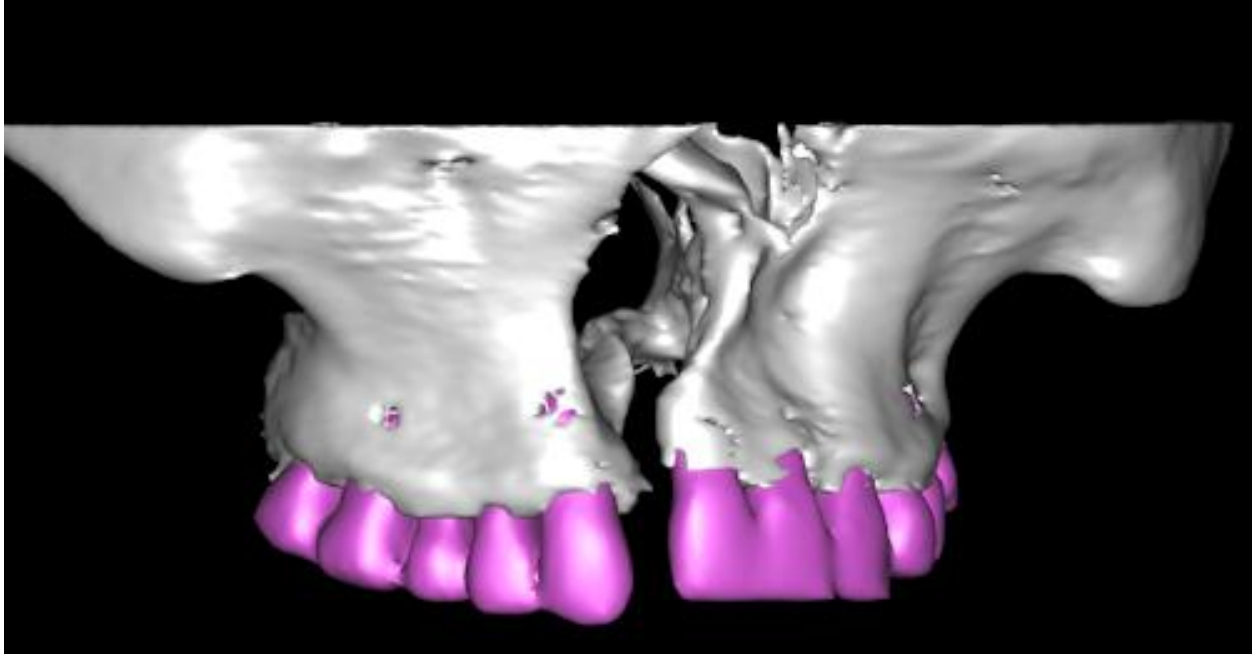
The images provided give a clear idea about the width and extension of the “gap” between the maxillary processes; they show also the abnormal anatomy of the nasal cavity and the severe deviation of the nasal septum. Number, direction and position of all the adjacent teeth are shown as well.

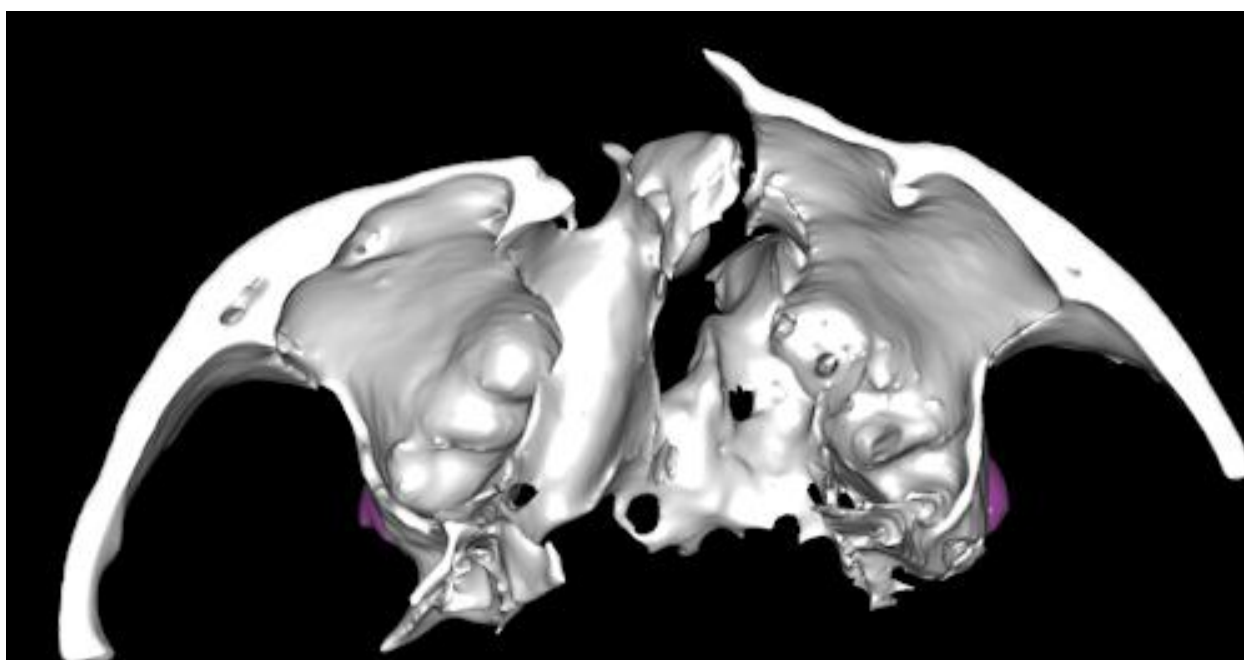
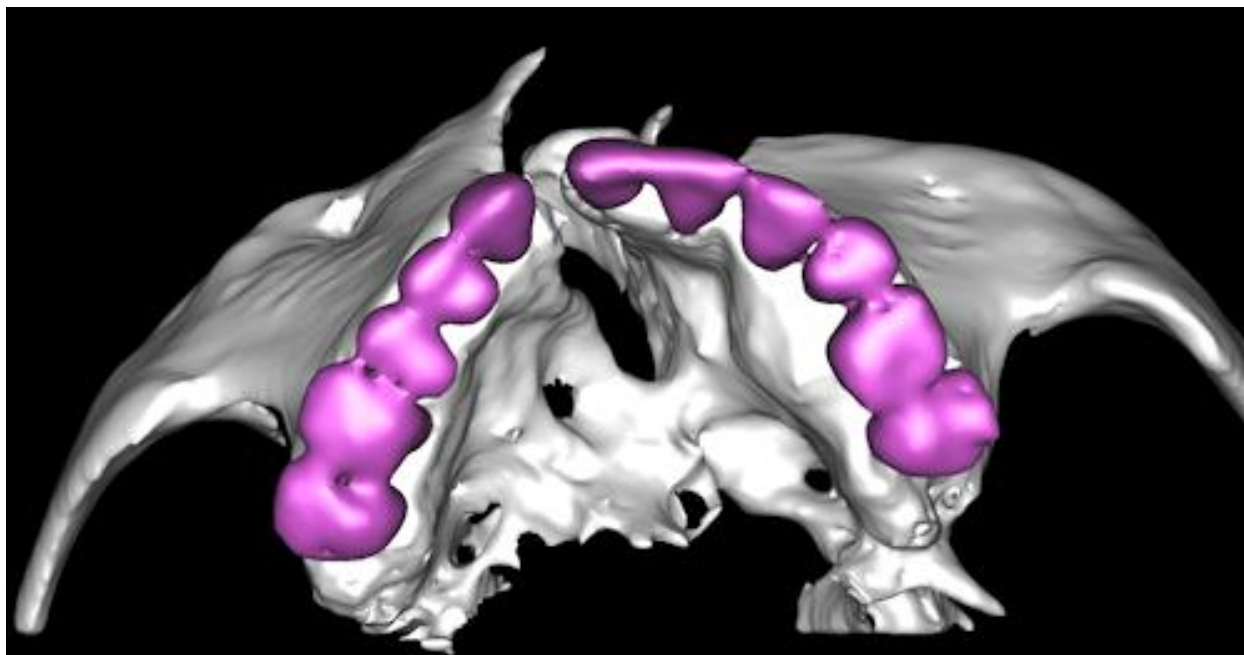
3D Processing by [3D Diagnostix, Inc.](#)











Mitra Sadrameli, DMD
Resident, Oral and Maxillofacial Radiology

Marcel Noujeim DDS MS
Program Director, Oral and Maxillofacial Radiology

Dept of Dental Diagnostic Science
University of Texas Health Science Center at San Antonio